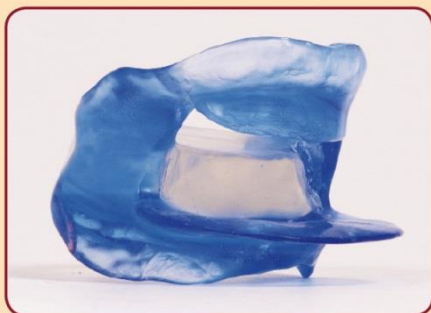

# Dental Protector®

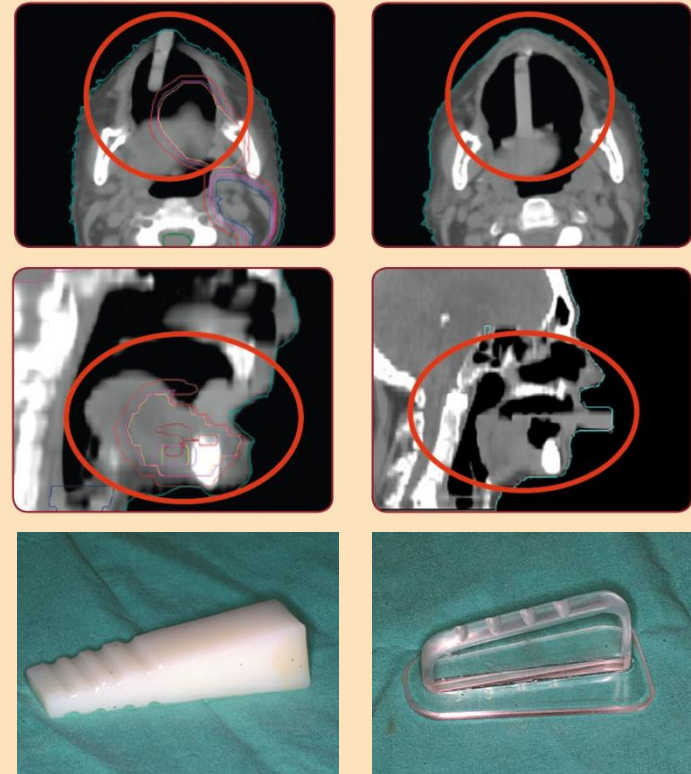
**The perfect protection for tele- and brachytherapy  
of head and neck tumors**



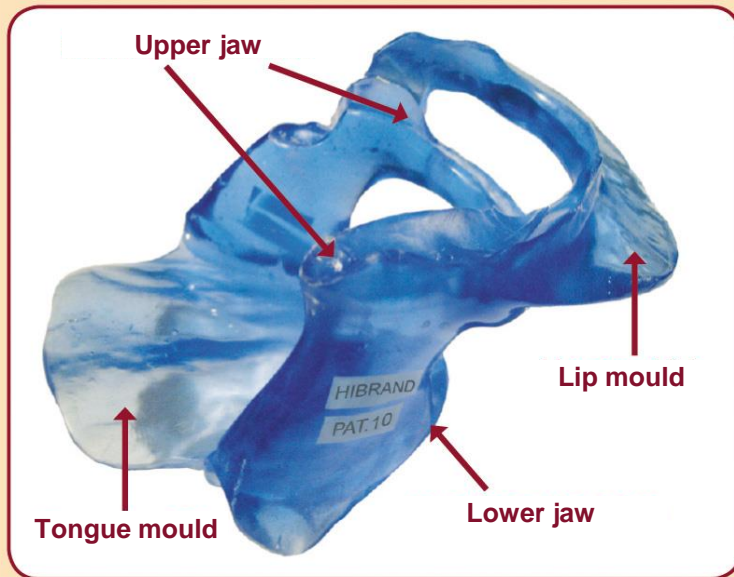
**HIBRAND**  
INDUSTRIES AG

# Problem

- No exact repeatable positioning of facial soft parts (tongue, lips, cheeks)
- No exact repeatable mouth opening

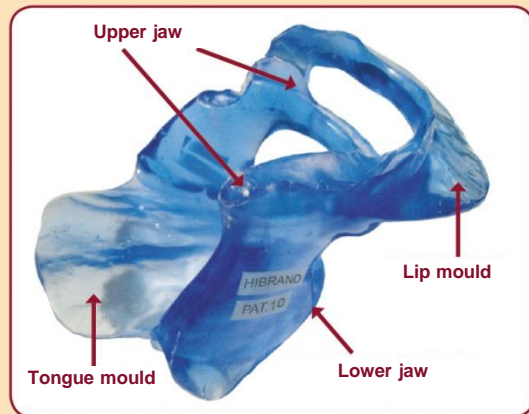


# OUR SOLUTION - DENTAL PROTECTOR®



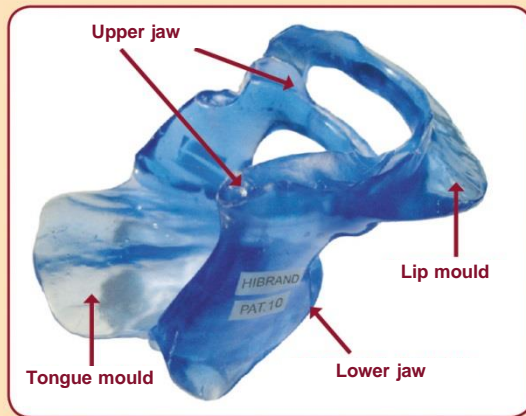
- **exact repetition of lower jaw and soft part position**
- **reduction of radiation side effects**
- **optimizing of the radiation target volume**

# DENTAL PROTECTOR®



- **individually produced for each patient**
- **independent of patient's denture**
- **takes into account patient's anatomy**
- **adaptable to special therapy requirements**
- **fulfils all GEC-ESTRO recommendations**
- **patented**
- **CE- certified procedure**

# DENTAL PROTECTOR®



- **daily exact repeatable:**
  - mouth opening**
  - tongue position**
  - lip position**
  - cheek position**

# Field of applications

- **Protection of facial soft parts  
(tongue, lips, cheeks)**

by

**Teletherapy  
Brachytherapy**

of

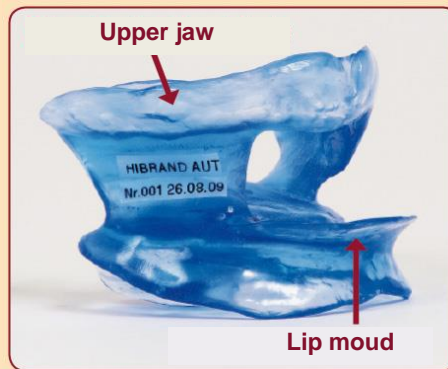
- **Tumors of the floor**
- **Oropharyngeal tumors**
- **Nasopharyngeal tumors**
- **Tumors of the nasal cavity  
and the paranasal sinuses**

# Clinical experiences

**EXAMPLE 1:** Radiation of (floor of mouth) squamous cell- tongue carcinoma

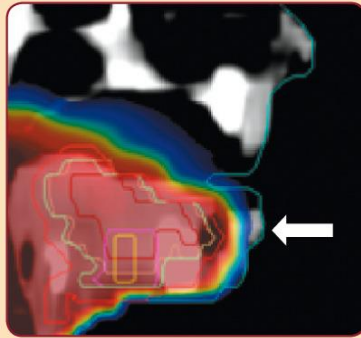
63 years, female, squamous cell- and tongue carcinoma, cT4  
cN0 M0 G2; neoadjuvante RTX 50 Gy, Mitomycin C, 5-FU

**THERAPY-GOAL:** Extensive radical radiation therapy under maximum protection of the lower jaw and upper jaw by using a tongue- and lip shield.

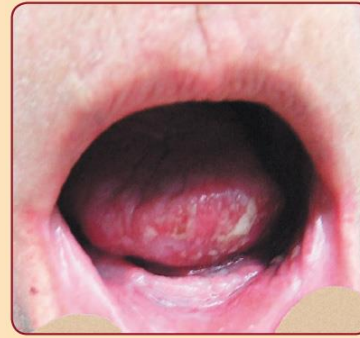

# Clinical experiences

**RESULT:** Operation: ypT0; no radiation side effects on the lower lip and upper jaw



Planning- CT with isodosedistribution:  
lower lip outside of high dosage area  
(arrow)



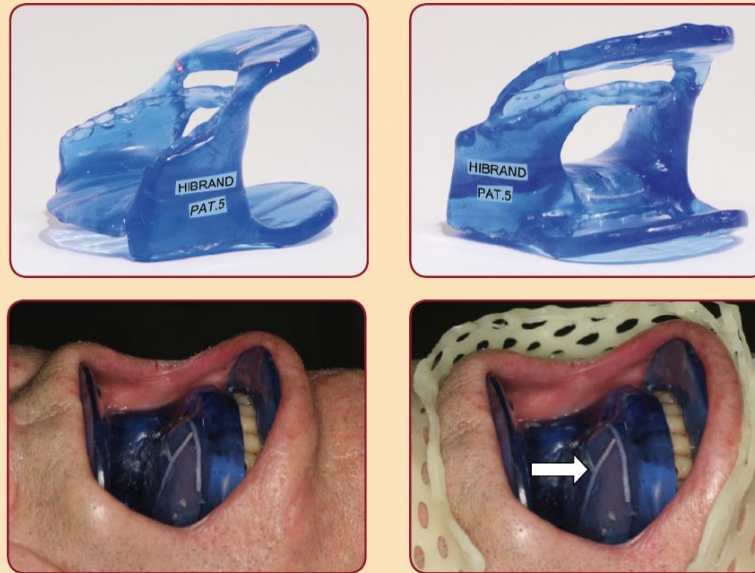End of radiotherapy: no radiation side  
effects in lower lip

**=> aim of therapy accomplished!**



# Clinical experiences

## EXAMPLE 2: displacement of lips and labial angles

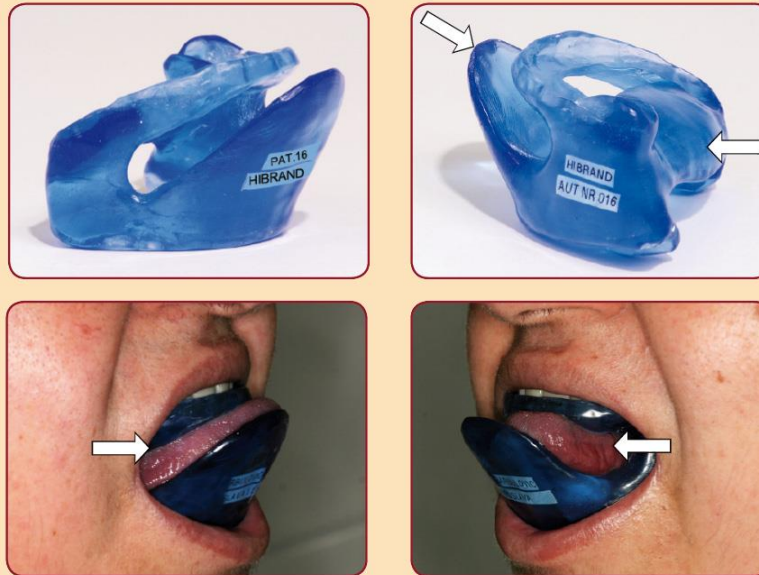


**Upper series:** Hibrand Dental Protector® with laterally accentuated lower and upper lip mould for anterior displacement of the labial angles.

**Lower series:** Hibrand Dental Protector® in situ with formation of a "duck's bill", thereby displacement of the lips and labial angles out of the lateral radiation fields. Radioopaque marking for better demarcation of the tongue (arrow) in the planning CT scan.

# Clinical experiences

## EXAMPLE 3: anterior tongue displacement

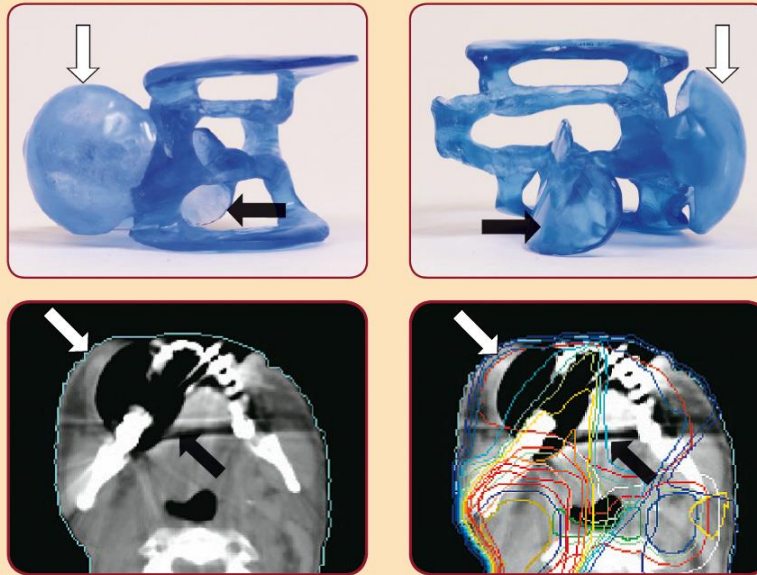


**Upper series:** Hibrand Dental Protector® with double tongue moulds (arrows) for active anterior displacement of the tongue.

**Lower series:** Hibrand Dental Protector® in situ with clinical active anterior displacement of the mobile tongue (arrows) moved out of radiation field.

# Clinical experiences

## EXAMPLE 4: cheek and tongue displacement



**Upper series:** Hibrand Dental Protector® with a lateral mould for cheek (arrow) and tongue displacement each (black arrow).

**Lower series:** Hibrand Dental Protector® in situ in the planning CT-scan: cheek (arrow) and tongue displacement (black arrow), displacement out of high dosage area.

# HIBRAND

## INDUSTRIES AG

**HIBRAND Industries AG · Industriering 7 · 9491 Ruggell · Liechtenstein**

**E-Mail: [hibrand@instrumentsag.li](mailto:hibrand@instrumentsag.li) · [www.hibrand.li](http://www.hibrand.li)**